

Two cases of thyroid sarcoidosis presentation as painful, recurrent goiter in patients with Graves' disease

Dois casos de sarcoidose na tireoide com apresentação na forma de bóciós recorrentes dolorosos em pacientes com doença de Graves

Piotr Kmieć¹, Marta Lewandowska¹, Anna Dubaniewicz², Krystyna Mizan-Gross³, Artur Antolak⁴, Barbara Wołyniak¹, Krzysztof Sworczak¹

SUMMARY

Sarcoidosis rarely involves the thyroid gland. Pain in the thyroid gland area was only sporadically reported in patients suffering from this disease. The aim of this paper is to report and discuss the cases of two female patients with Graves' disease who presented painful, rapidly growing, recurrent goiters (after strumectomy in their early adult lives). Invasive treatment was applied and sarcoidosis was revealed histologically. The first patient suffered from dysphagia and dyspnoea due to large goiter; skin lesions were present as well. Sarcoidosis was diagnosed in histological examination of the thyroid tissue specimens. Steroid treatment was ineffective; thus, the thyroid was removed. Two years later thyroid sarcoidosis recurred as a painful goiter and surgical treatment was applied once again. In the second case, thyroid ultrasound findings suggesting malignancy, and prompted the decision to perform thyroidectomy despite the fact that FNAB (fine needle aspiration biopsy) revealed cells indicative of a "granulomatous disease in the post-resection scar" and results of the thorax high-resolution computed tomography scan suggested pulmonary sarcoidosis. Pathological examination confirmed sarcoidosis. However, a papillary cancer focus was also found. *Arq Bras Endocrinol Metab.* 2012;56(3):209-14

¹ Department of Endocrinology and Internal Medicine, Medical University of Gdansk, Gdansk, Poland

² Department of Pneumology, Medical University of Gdansk, Gdansk, Poland

³ Department of Nuclear Medicine, Medical University of Gdansk, Gdansk, Poland

⁴ Department of Pathology, St. Adalbert Specialist Hospital, Gdansk, Poland

SUMÁRIO

A sarcoidose raramente envolve a glândula tireoide, e apenas esporadicamente foi relatada dor na região da glândula em pacientes que sofrem dessa doença. O objetivo deste trabalho é relatar e discutir os casos de duas mulheres que apresentavam bóciós dolorosos, de rápido crescimento e recorrentes (após tireoidectomia na adolescência). Foi usado um tratamento invasivo e a sarcoidose foi revelada pelos achados histológicos. A primeira paciente sofria de disfagia e dispneia em decorrência de um grande bócio; lesões cutâneas também estavam presentes. A sarcoidose foi diagnosticada em um exame histológico das amostras de tecido da tireoide. O tratamento com esteroides foi ineficaz; foi feita assim a ressecção da glândula. Dois anos depois, houve recidiva da sarcoidose da tireoide como um bócio doloroso, e o tratamento cirúrgico foi feito mais uma vez. No segundo caso, os resultados do ultrassom da tireoide sugeriam malignidade e levaram à decisão de se realizar a tireoidectomia, apesar de as células de PAAF indicarem uma doença granulomatosa na cicatriz pós-ressecção e os resultados da tomografia computadorizada de alta resolução de tórax sugerirem sarcoidose pulmonar. O exame histopatológico da glândula revelou sarcoidose. Entretanto, também foi encontrado um foco de câncer papilar. *Arq Bras Endocrinol Metab.* 2012;56(3):209-14

Correspondence to:

Piotr Kmieć
Department of Endocrinology,
Medical University of Gdansk,
7 Debinki Street
80-952 – Gdansk, Poland
piotrkmiec@gmail.com

Received on 21/Nov/2011
Accepted on 18/Mar/2012

INTRODUCTION

Sarcoidosis (SA) is a multisystemic, idiopathic disease that may affect almost all organs, most commonly lungs, the lymph nodes, liver, spleen and skin (1,2). In

the etiology of SA, infectious, genetic and autoimmune factors have been proposed. The suggested pathophysiologic mechanism of the disease involves an undetermined, probably infectious antigen(s) triggering an au-

to immune reaction in genetically predisposed individuals (3,4). As a result, non-caseating, epithelioid granulomas are formed. Presence of these formations in histological examination, along with clinical and radiological findings enables SA diagnosis as long as “granulomas of known causes and local sarcoid reactions” are excluded (5).

As has been extensively reported, sarcoidosis coexists with autoimmune thyroid disease (ATD), although the frequency of this association varies largely between studies, i.e., ATD percentage ranges from 1.9% to 16.6% of SA patients (6-10). The prevalence of anti-thyroid antibodies (anti-TPO: anti-thyroperoxidase antibodies, and anti-Tg: anti-thyroglobulin antibodies) and Hashimoto's disease was higher in sarcoidosis patients than in age- and gender-matched control subjects (11). Moreover, primary hypofunction of the gland was frequently reported (7,12,13). Although the incidence of hyperthyroidism is considered rare (14), one study showed a significantly higher prevalence of Graves' disease in SA patients than in matched controls (11). On the one hand, *HLA* gene association between Graves' disease and sarcoidosis has been established (15). On the other hand, Graves' disease in SA patients may only be coincidental (14). Other thyroid disorders that accompany sarcoidosis include goiter, de Quervain's thyroiditis and thyroid cancer (9,16).

Thyroid infiltration by noncaseating granulomas in the course of sarcoidosis diagnosed in other organs is rare. In a review paper from 1993, Valiati and cols. found 40 patients with thyroid sarcoidosis in the literature (17). Although in autopsy studies showed sarcoid granulomas in the gland in approximately 4% to 4.5% SA subjects, less than 1% of sarcoidosis patients presented significant clinical involvement of the thyroid (7,9,18,19). In these cases, infiltration was associated with hypo-, eu- or hyperthyroidism (9,16,20) and may be manifested as or imitate thyroiditis, nodular and diffuse goiter, and thyroid cancer (2,9,21,22).

To our knowledge, painful thyroid sarcoidosis was reported only sporadically (23-25). In this paper, we are going to present the cases of two female patients with Graves' disease who suffered from painful, rapidly growing, recurrent goiter due to thyroid sarcoidosis.

CASE REPORTS

Patient A

The patient case was already partially reported in 2008 (26).

A middle-aged woman with several co-morbidities (after strumectomy in her early adult life) was admitted

to our clinic due to rapidly growing, painful recurrent goiter (Table 1). She reported increasing, lower neck swelling leading to dysphagia, dyspnea and choking, which had started approximately 10 weeks prior to hospital admission. Upon physical examination, the left lobe of the thyroid was enlarged, and there were skin lesions above the gland, as well as on the left shoulder and calf (Table 1).

Laboratory findings revealed no significant abnormalities apart from increased erythrocyte sedimentation rate (ESR; Table 1).

Thyroid cytology by fine needle aspiration biopsy (FNAB) indicated de Quervain's thyroiditis (Figure 1A). However, histological examination of the tissue material from the thyroid and affected skin suggested sarcoidosis (Figure 2A). Despite oral steroid therapy implementation, dyspnea and dysphagia became exacerbated, and a new strumectomy was carried out. After the surgery, symptoms subsided. The patient was prescribed a daily prednisone dose of 10 milligrams.

Nevertheless, twenty months later, the granulomatous disease recurred in the thyroid lodge, presented as a painful movable tumour causing dyspnoea and stridor. Exudative, nodular skin lesions were present in the strumectomy scar area and other body regions. Following ultrasound and thyroid FNAB, the patient was qualified for another goiter resection. During hospitalization, a thorax high-resolution computed tomography (HR-CT) scan suggested stage I sarcoidosis in the lungs (the X-ray image from two years earlier was normal).

Currently, our patient remains under outpatient clinic care and receives a daily L-thyroxine dose of 125 micrograms.

Patient B

An 49 year-old female with Graves' disease, who appeared for regular checkups in our outpatient clinic due to recurrent goiter after strumectomy in her early adult life, reported pain in the thyroid region that lasted for about four weeks. It radiated toward the pharynx and was accompanied by a pulling sensation (Table 1). Laboratory examinations revealed no significant abnormalities (Table 1).

Ultrasound examination showed a considerably enlarged thyroid gland with multiple focal lesions. Also, malignancy features were found by ultrasound in the post-resection scar area (Table 1). FNAB cytology showed histiocyte infiltrate, which suggested granulomatous disease in the scar tissue area (Figure 1B); no neo-

plasmatic cells were found. Furthermore, the results of the thorax HR-CT scan suggested stage 2 pulmonary sarcoidosis. Despite thyroid FNAB and thorax CT results the patient was qualified for surgery. In histological examination, thyroid sarcoidosis was confirmed

(Figure 2B): numerous sarcoid granulomas were present in both lobes of the gland, in one lymph node, in surrounding subcutaneous tissues, and in the adjacent skin. Moreover, a 4 by 2-mm focus of papillary thyroid cancer was found in the right lobe (Figure 3).

Table 1. Results of clinical and additional examinations

Age at SA diagnosis	Patient A 52	Patient B 49
Admission date	26.12.2006	24.11.2010
Primary thyroid disease	Graves'	Graves'
Age at strumectomy	21	26
Co-morbidities	Resistant hypertension, <i>diabetes mellitus</i> , obesity, HCV infection, post spinal column surgeries	None
Symptoms	Rapidly growing, painful, recurrent goitre, dysphagia, dyspnea	Pain of the thyroid region radiating toward the pharynx; pulling sensation
Signs	Thyroid's left lobe enlargement, edematous nodules and hard infiltration of the skin above the gland	Redness and hyperesthesia of the skin above the thyroid
Laboratory results	TSH = 1.51 uU/mL, fT4 = 17.45 pmol/L, ESR = 37 mm, CRP < 5 mg/L	TSH = 0.87 uU/mL, fT4 = 19,1 pmol/L, CRP < 5 mg/L
Thyroid gland ultrasound	Heterogeneous thyroid tissue with altered echogenicity, volume of left lobe 6.4 mL, volume of right lobe 14.3 mL	Multiple, solid foci, up to 3 cm in diameter with fluid-filled areas and calcifications; neoplasm characteristics in the post-resection scar; two pathologic supraclavicular lymph nodes, thyroid gland volume 102 mL
FNAB	Histiocyte infiltration, multinucleated cells (Figure 1A)	Histiocyte reaction with cells indicative of a granulomatous disease in strumectomy scar (Figure 1B)
Treatment	Ineffective steroid therapy, consecutive partial thyroidectomy (02.2007)	Thyroidectomy (01.2011)
Lung involvement	Stage 1 pulmonary sarcoidosis reported two years after thyroid sarcoidosis diagnosis in a HR-CT scan (01.2009)	Stage 2 pulmonary sarcoidosis found in a HR-CT scan (01.2011)
Remission/recurrence	Jan., 2009. Thyroid sarcoidosis recurrence as painful goiter – second re-strumectomy (02.2009); currently in remission	Currently in remission

CRP: C-reactive protein; ESR: erythrocyte sedimentation rate; fT4: free thyroxine; HR-CT: high resolution computed tomography; TSH: thyroid-stimulating hormone.

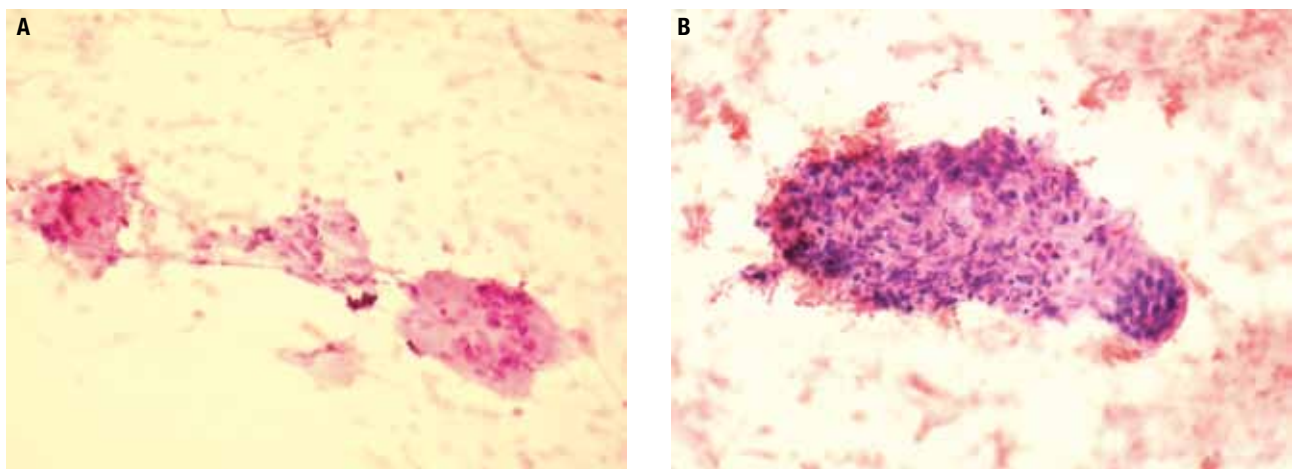


Figure 1. FNAB specimens. HE x200. **A.** Multinucleated cells with a histiocyte granulomatosis (patient A); **B.** Histiocyte granulomatosis fragment with adjacent multinucleated cells (patient B). HE: hematoxylin-eosin staining.

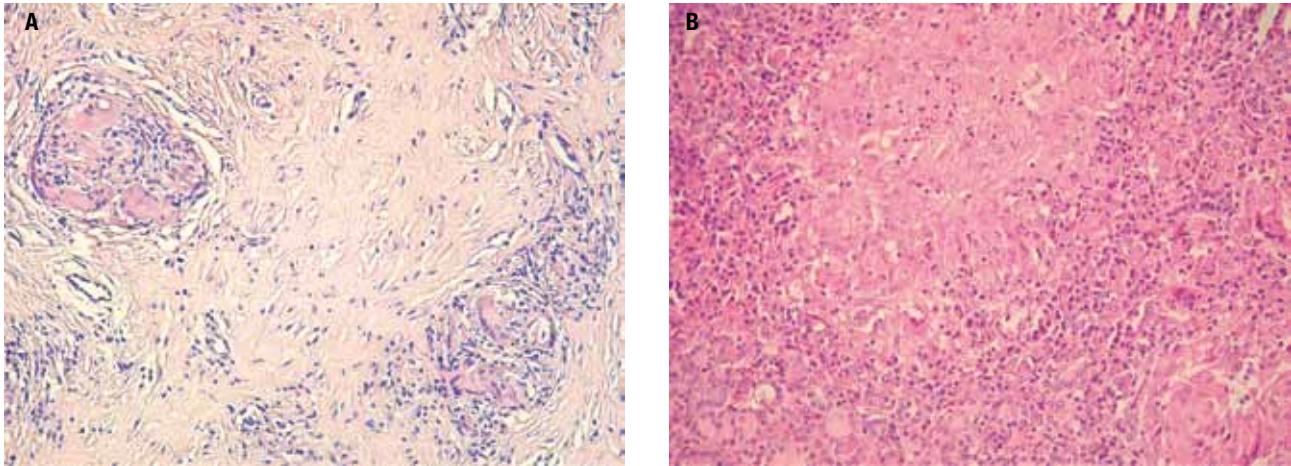


Figure 2. Thyroid sarcoidosis. HE x200. **A.** Diffused fibrosis between sarcoid granulomas (patient A); **B.** Sarcoid granuloma (patient B). HE: hematoxylin-eosin staining.

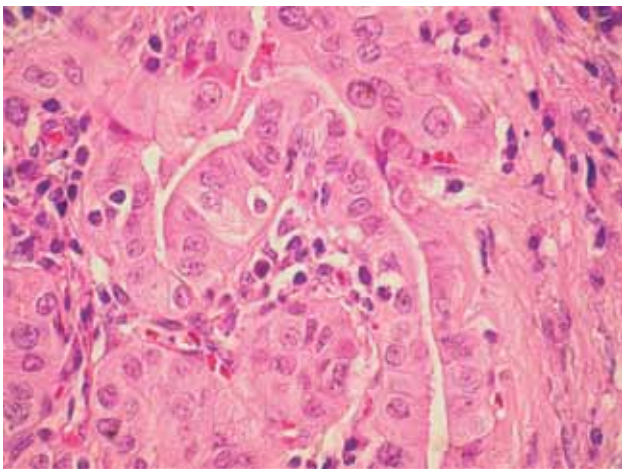


Figure 3. Microfocus of papillary thyroid cancer (patient B). HE x400. HE: hematoxylin-eosin staining.

At present, the patient remains under care of our outpatient clinic. She receives a daily dose of 100 micrograms of L-thyroxine.

REVIEW OF LITERATURE AND DISCUSSION

As mentioned above, thyroid sarcoidosis is rarely diagnosed *in vivo*, although non-caseating granulomas are found *post-mortem* in up to 4.5% of SA patients. In clinically significant thyroid sarcoidosis, abnormalities in respect to gland morphology (i.e., nodules, goiter, thyroiditis) and function (hypo- and hyperthyroidism) may be isolated or combined. A different criterion for categorizing thyroid sarcoidosis patients is the involvement of other organs; in this respect, concomitant SA

manifestation in the lungs is more frequent than isolated thyroid infiltration.

Three main groups of patients with thyroid sarcoidosis emerge from the literature review. First, patients in whom the disease manifested in the form of (possibly incidental) thyroid nodule or nodules – associated with or not with goiter (2,6,27,28). Functional disorders of the glands are not apparent.

Second, several reported cases of thyroid sarcoidosis involved patients who presented thyrotoxicosis (14,29-31). Concomitant Graves' disease was found in three men and one woman, aged 23 to 30; all were resistant to anti-thyroid treatment and, therefore, underwent thyroidectomy (14,29-31). Two other hyperthyroid patients, in a much greater extent, resembled the first group of thyroid sarcoidosis subjects, since their main clinical abnormality was the multi-nodular goiter, and not thyrotoxicity (29,32).

Finally, instances of thyroid sarcoidosis in the context of gland tumours must be mentioned. In several patients, sarcoidosis of the thyroid mimicked tumors of the gland; only post-operative histological examination of the thyroid showed the correct diagnosis (22,33,34). Other reports involved a sarcoid reaction due to thyroid papillary cancer developing in the gland itself, or found in regional lymph nodes (16,35). In both publications, papillary thyroid cancer was diagnosed before sarcoid-like lesions were found in histology (apart from the tumor). Sarcoid reactions have been described as non-caseating granulomas, identical to those of systemic sarcoidosis, found in the primary tumours, their vicinity, or within the lymph nodes draining the neoplasms,

when evidence of systemic SA is absent (35,36). These reactions contrast with sarcoidosis accompanying a malignant tumour. The latter case is exemplified by one of our patients (patient B), and has also been reported by other authors (21,31,37).

To our knowledge, concomitant occurrence of papillary cancer, Graves' disease and thyroid sarcoidosis, which we present here, had only been reported once before, by Zimmermann-Belsing and cols. (31). Their patient, known to have sarcoidosis, underwent total thyroidectomy because of inadequate control of hyperthyroidism with thiamazole treatment in the course of Graves' disease (the goiter gradually enlarged). Thyroid sarcoidosis and papillary cancer of the gland with metastases to the lymph nodes were incidental findings in histological examination. In patient B (described here), ultrasound characteristics were disturbing, although FNAB result did not support the suspicion of cancer, and thorax CT scan suggested pulmonary sarcoidosis. In case of suspicion of malignancy, the approach should aim at clarifying diagnosis.

A case similar to ours in these aspects (i.e., malignancy suspicion and surgical treatment) was reported by María González-Gasch and cols. (25). Their patient, who had undergone left hemithyroidectomy due to follicular cancer of the thyroid fifteen years earlier and had been diagnosed with sarcoidosis two years earlier, presented a painful nodule in the right lobe region of the thyroid. Due to the need to exclude malignancy (and the absence of inflammatory signs), the female patient reported by the Spanish authors underwent right hemithyroidectomy. Thyroid sarcoidosis was diagnosed histologically.

Obviously, the three groups of patients with thyroid sarcoidosis reviewed above do not exhaust all possible manifestations of the disease. Our first patient presented here may serve as an example. Initially, subacute thyroiditis was suspected in patient A, based on painful goiter, increased ESR (although, importantly, it did not exceed 40 mm/h) and result of FNAB cytology. Although tissue specimens revealed thyroid sarcoidosis, the exclusion of an underlying (i.e., sarcoid reaction) or accompanying malignancy could not have been made without thyroidectomy. A similar case was reported by Cooke – his patient also presented dysphagia and dyspnea due to large goiter, leading to suspicion of malignancy, and was proven negative after surgery (38).

Yet, an other differential diagnosis (apart from thyroid sarcoidosis) should be considered in cases such as that of patient A or the one reported by Cooke, i.e.,

anaplastic cancer of the thyroid manifesting as subacute, granulomatous inflammation of the gland. Patients with this diagnosis were reported by Mizan-Kalisiak and cols. as well as Rosen and cols. (39,40). In the first instance, steroid, antibiotic and salicylate treatment were ineffective. The tissue specimens obtained during thyroid surgery and post-mortem examination of Cooke's patient revealed anaplastic carcinoma of the gland. In this case, diagnosis was also based on histological examination of the gland (in samples collected during tracheostomy).

CONCLUSIONS

Similar to previous reports, other diseases were suspected in our patients before the diagnosis of sarcoidosis was determined by histology. Not only is thyroid sarcoidosis a rare condition, but it also may manifest in many different forms. Furthermore, the diagnosis may only be confirmed if known causes of granulomas and, in particular, sarcoid reactions, are excluded.

In summary, it should be underscored that, in the vast majority of cases, sarcoid involvement of the thyroid remains clinically insignificant. The emergence of gland disorders (change in function or morphology) is not associated with pain. The process is mild and frequently leads to hypothyroidism. However, sporadically, sarcoidosis can cause pain and compression symptoms, and may coexist with thyroid cancer. One should also bear in mind that papillary thyroid carcinoma may cause a sarcoid-type reaction in the gland. Therefore, in patients with suspected thyroid sarcoidosis, thorough diagnosis and observation are necessary. Often, particularly due to the diagnostic difficulties, surgery is indicated.

Funding: this research did not receive any specific grant from any funding agency in the public, commercial or non-profit sector.

Disclosure: no potential conflict of interest relevant to this article was reported.

REFERENCES

1. Bell NH. Endocrine complications of sarcoidosis. *Endocrinol Metab Clin North Am.* 1991;20(3):645-54.
2. Ozkan Z, Oncel M, Kurt N, Kargi AB, Ozdemir N, Kaptanoglu L, et al. Sarcoidosis presenting as cold thyroid nodules: report of two cases. *Surg Today.* 2005;35(9):770-3.
3. Dubaniewicz A. Mycobacterium tuberculosis heat shock proteins and autoimmunity in sarcoidosis. *Autoimmun Rev.* 2010;9(6):419-24.
4. Rosen Y. Pathology of sarcoidosis. *Semin Respir Crit Care Med.* 2007;28(1):36-52.

5. Statement on sarcoidosis. Joint Statement of the American Thoracic Society (ATS), the European Respiratory Society (ERS) and the World Association of Sarcoidosis and Other Granulomatous Disorders (WASOG) adopted by the ATS Board of Directors and by the ERS Executive Committee, February 1999. *Am J Respir Crit Care Med.* 1999;160(2):736-55.
6. Cabibi D, DiVita G, La Spada E, Tripodo C, Patti R, Montalto G. Thyroid sarcoidosis as a unique localization. *Thyroid.* 2006;16(11):1175-7.
7. Gentilucci UV, Picardi A, Manfiini S, D'Avola D, Costantino S, Pozzilli P. Granulomatous thyroiditis: an unexpected finding leading to the diagnosis of sarcoidosis. *Acta Biomed.* 2004;75(1):69-73.
8. Isern V, Lora-Tamayo J, Capdevila O, Villabona C, Mañá J. Sarcoidosis and autoimmune thyroid disease. A case series of ten patients. *Sarcoidosis Vasc Diffuse Lung Dis.* 2007;24(2):148-52.
9. Porter N, Beynon HL, Randeva HS. Endocrine and reproductive manifestations of sarcoidosis. *QJM.* 2003;96(8):553-61.
10. Papadopoulos KI, Hörnblad Y, Liljebadh H, Hallengren B. High frequency of endocrine autoimmunity in patients with sarcoidosis. *Eur J Endocrinol.* 1996;134(3):331-6.
11. Antonelli A, Fazzi P, Fallahi P, Ferrari SM, Ferrannini E. Prevalence of hypothyroidism and Graves disease in sarcoidosis. *Chest.* 2006;130(2):526-32.
12. Ilias I, Panoutsopoulos G, Batsakis C, Nikolakakou D, Filippou N, Christakopoulou I. Thyroid function and autoimmunity in sarcoidosis: a case-control study. *Croat Med J.* 1998;39(4):404-6.
13. Nakamura H, Genma R, Mikami T, Kitahara A, Natsume H, Andoh S, et al. High incidence of positive autoantibodies against thyroid peroxidase and thyroglobulin in patients with sarcoidosis. *Clin Endocrinol (Oxf).* 1997;46(4):467-72.
14. Yarman S, Kahraman H, Tanakol R, Kapran Y. Concomitant association of thyroid sarcoidosis and Graves' disease. *Horm Res.* 2003;59(1):43-6.
15. Muzaffar TH, Al-Ansari JM, Al-Humrani H. Brief review of sarcoidosis of the thyroid gland. *Int J Med Sci.* 2009;1(3):44-5.
16. Yamauchi M, Inoue D, Fukunaga Y, Kakudo K, Koshiyama H. A case of sarcoid reaction associated with papillary thyroid carcinoma. *Thyroid.* 1997;7(6):901-3.
17. Mihailovic-Vucinic V, Sharma OP. Atlas of sarcoidosis: pathogenesis, diagnosis, and clinical features. Springer; 2005. p. 103-4.
18. Winnacker JL, Becker KL, Katz S. Endocrine aspects of sarcoidosis. *New Engl J Med.* 1968;278:483-92.
19. Sharma OP, Vucini V. Sarcoidosis of the thyroid and kidneys and calcium metabolism. *Semin Respir Crit Care Med.* 2002;23(6):579-88.
20. Gostiljac DM, Dordevic PB, Maric-Zivkovic J, Canovic F. Sarcoidosis localized in endocrine glands. *Med Pregl.* 2005;58 Suppl 1:25-9.
21. Bruins NA, Oswald JE, Morreau H, Kievit J, Pavel S, Smelt AH. Papillary thyroid carcinoma in a patient with sarcoidosis treated with minocycline. *Neth J Med.* 2007;65(5):185-7.
22. Mizukami Y, Nonomura A, Michigishi T, Ohmura K, Matsubara S, Noguchi M. Sarcoidosis of the thyroid gland manifested initially as thyroid tumor. *Pathol Res Pract.* 1994;190(12):1201-5; discussion 1206-7.
23. Cilley RE, Thompson NW, Lloyd RV, Shapiro B. Sarcoidosis of the thyroid presenting as a painful nodule. *Thyroidology.* 1988;1(1):61-2.
24. Johnson LW, Sehon JK, McDonald JC. Diagnosis and management of a painful thyroid nodule in a patient with systemic sarcoidosis. *J La State Med Soc.* 2000;152(3):125-7.
25. María González-Gasch A, Mora Rufete A, Moltó Marhuenda J, Martín-Hidalgo A. Thyroid sarcoidosis in a woman with previous thyroid cancer. *Med Clin (Barc).* 2002;119(8):316-7.
26. Mizan-Gross K, Lewczuk A, Wołyniak B, Antolak A, Sworczak K. Izolowana sarkoidoza tarczycy: opis przypadku. *Endokrynol Pol.* 2008;59(supl. A):133-4.
27. Lemerre D, Caron F, Delval O, Goujon JM, Hira M, Meurice JC, et al. Thyroid manifestations of sarcoidosis: a case report. *Rev Pneumol Clin.* 1999;55(6):393-6.
28. Warshawsky ME, Shannies HM, Rozo A. Sarcoidosis involving the thyroid and pleura. *Sarcoidosis Vasc Diffuse Lung Dis.* 1997;14(2):165-8.
29. Papi G, Briganti F, Artioli F, Cavazza A, Carapezzi C, Roggeri A, et al. Sarcoidosis of the thyroid gland associated with hyperthyroidism: review of the literature and report of two peculiar cases. *J Endocrinol Invest.* 2006;29(9):834-9.
30. Rodriguez MC, Rani D, Faas FH. Unusual clinical course of Graves' thyrotoxicosis and concomitant sarcoidosis: case report and review of literature. *Endocr Pract.* 2007;13(2):159-63.
31. Zimmermann-Belsing T, Christensen L, Hansen HS, Kirkegaard J, Blichert-Toft M, Feldt-Rasmussen U. A case of sarcoidosis and sarcoid granuloma, papillary carcinoma, and Graves' disease in the thyroid gland. *Thyroid.* 1997;7(6):901-3.
32. Langsteger W, Lind P, Beham A, Kölringer P, Eber O. Isolated thyroid gland sarcoidosis and hyperthyroidism. *Schweiz Med Wochenschr.* 1989;119(17):544-8.
33. Saydam L, Bozkurt MK, Kutluay L, Özçelik T. Sarcoidosis of the thyroid gland initially diagnosed as malignancy. *Otolaryngol Head Neck Surg.* 2003;129(1):154-6.
34. van Assendelft AH, Kahlos T. Sarcoidosis of the thyroid gland. *Sarcoidosis.* 1985;2(2):154-6.
35. Komatsu M, Itoh N, Yazawa M, Kobayashi S, Inoue K, Kuroda T. Sarcoid reaction in thyroid diseases: report of a case of thyroid carcinoma demonstrating sarcoid reaction in regional lymph nodes. *Endocr J.* 1997;44(5):697-700.
36. Nag S. Sarcoidosis diagnosis and management. Motamedi MHK, editor. InTech, October, 2011.
37. Middleton WG, deSouza FM, Gardiner GW. Papillary carcinoma of the thyroid associated with sarcoidosis. *J Otolaryngol.* 1985;14(4):241-4.
38. Cooke R. Sarcoidosis of thyroid. *Proc R Soc Med.* 1959;52(3):174-5.
39. Mizan-Kalisiak K, Sworczak K, Markuszewska A, Warnke D. Anaplastic carcinoma of the thyroid gland with the clinical course suggesting subacute thyroiditis—personal observations. *Pol Arch Med Wewn.* 1988;79(5):278-82.
40. Rosen F, Row VV, Volpe R, Ezrin C. Anaplastic carcinoma of the thyroid with abnormal circulating iodoprotein: a case simulating subacute thyroiditis. *Can Med Assoc J.* 1966;95(20):1039-41.